

Ultrastructural analysis of degenerative changes of spermatogonia of Salmonidae from Ohrid lake during spermatogenesis

Irena Tavchiovaska-Vasileva

Institute of Biology, Faculty of Natural Sciences and Mathematics, Gazi Baba b.b., P. O. 162, 1000 Skopje, Republic of Macedonia
irena@pmf.ukim.mk

Abstract

The purpose of these article is to represent the cytomorphological aspect of the spermatogonia in Ohrid trout (*Salmo letnica* (Karaman, 1924) and Ohrid belvica (*Salmo ohridanus* Steindachner, 1892) on ultrastructural level, which degenerate in the postspawning period. At certain sites in the wall of the seminiferous lobules of Ohrid trout and Ohrid belvica, in addition to normal spermatogonia, there are some that show clear signs of degeneration and are characterized by asymmetric shape, granular or vacuolated cytoplasm, condensed chromatin, and karyopicnotic features.

On a level with certain lobules spermatogonia which separate from the walls of the lobules can be observed. We can notice presence of completely homogenous mass which originates from spermatogonia with delaminated cell membrane, as well as mitochondria with disintegrated crusts, vacuoles and poor cytoplasm or lysed parts of the cytoplasm. It has to be noted that spermatogonia which are situated next to the Sertoli cells are degenerated, as well as the Sertoli cells are. Our results which concern the cytomorphological characteristics of the spermatogonia which degenerate during the postspawning period correspond with findings of many other authors, as well as our previous results which concern the same or other teleost species. Our results show that in the period of rebuilding of the testicular parenchyma (postspawning period) the degenerative changes which are visible on a level with the spermatogonial population, should be explained as normal accompanying phenomenon which follows the initial phase of the future reproductive cycle whose intensive development happens in the later period, period of regeneration.

Key words: Ohrid trout, Ohrid belvica, degenerated spermatogonia, ultrastructural analysis, annual reproductive cycle.

INTRODUCTION

In this paper the degenerative changes on the level of spermatogonia have been analysed, as a normal accompanying phenomenon of spermatogenesis during the beginning phase of the annual reproductive cycle. In the literature there are relatively a small number of data which point out the degenerative changes of spermatogonia with Teleostei during the annual reproductive cycle (Almeida et al., 2008; Leal et al., 2009; Print & Loveland, 2000). The degeneration of some spermatogonia with *Perca fluviatilis* Linnaeus, 1758 was noticed by Kulaev (1927). Also, in the testes perch from Dojran Lake the presence of spermatogonia which show visible signs of degeneration was noticed (Tavchiovaska-Vasileva,

1992, 1994). In the postspawning period with *Perca fluviatilis* from Dojran Lake the presence of necrotic formations of spermatogonial origin was noticed (Tavchiovaska-Vasileva, 1992, 1994). Similar formations, i. e. necrotic (lipophuscine) groups with *Fundulus heteroclitus* (Linnaeus, 1766) were noticed by Matthews (1938) and Lofts et al. (1966). Necrotic formations rich with lipids and PAS positive cells in the testes of *Salaria pavo* (Risso, 1810) were noticed (Patzner & seiwald, 1987). The spermatogonial degeneration in the testes of Salmonidae, i.e. Ohrid trout and Ohrid belvica was noticed by Dimovska & Tavchiovaska-Vasileva (1998), Tavchiovaska-Vasileva (1999, 2001, 2002, 2004) and Tavchiovaska-Vasileva & Rebok (2009).

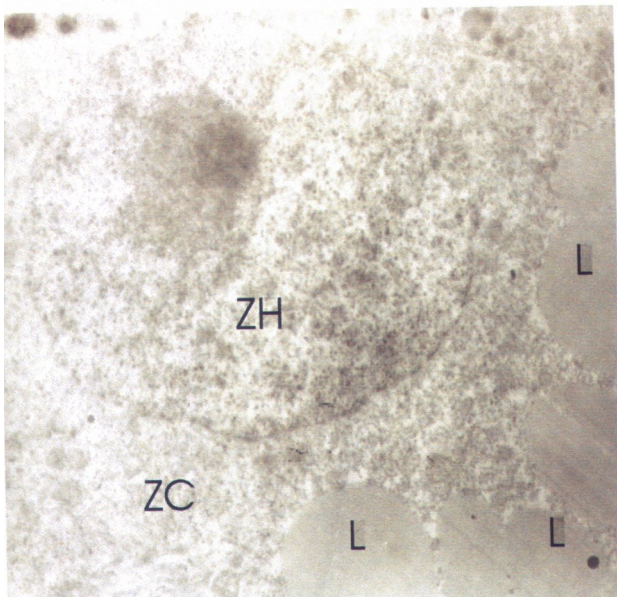


Fig. 1 Spermatogonium in beginning phase of degeneration with granular cytoplasm (ZC) and granular chromatin (ZH) in Ohrid trout. Presence of lipids (L) with low electron density. Ultrathin section, 7.000x

MATERIAL AND METHODS

Testes of sexually mature Ohrid trout and Ohrid belvica males caught in Ohrid Lake have been analysed. Analyses have been done with electronic microscope. Small parts of testes 1-2 mm big have been used for electronic microscopy. The material has been fixed according to following procedure: Immediately after the tissue sections have been taken, they are fixed in 3% glutaraldehyde and then conserved in 0.1 M phosphate buffer. After adequate fixation the material has been subnitted to postfixation in 1% osmium tetraoxid (OsO₄). In the further treatment the material has been washed in phosphate buffer, dehydrated in series of acetone and uranyl acetate. The tissue parts have been infiltrated with Durcopan ACM mixture, mixture of acetone-Durcopan, Durco-pan No.1, Durcopan No. 2, fit in Durcopan No. 2 and polymerised. For the ultrastructural analysis, ultrathin sections of 40-60 nm thickness have been prepared, with the help of glass knives, on Reichert-Yung "Ultracut" ultramicrotome, installed on copper nets, contrasted with uranyl acetate and lead citrate. The sections have been observed on Tesla BS 500 and OPTON (Zeiss) EM 109 electronic microscope. The micro-photographs for electronic microscope were obtained on Agfa Scientia EM Film 23056/6,5 x 9 cm, ORWO NP 20 panchromatic 120, Kodak 120 and made on Agfa papirtone Paper P1-3.

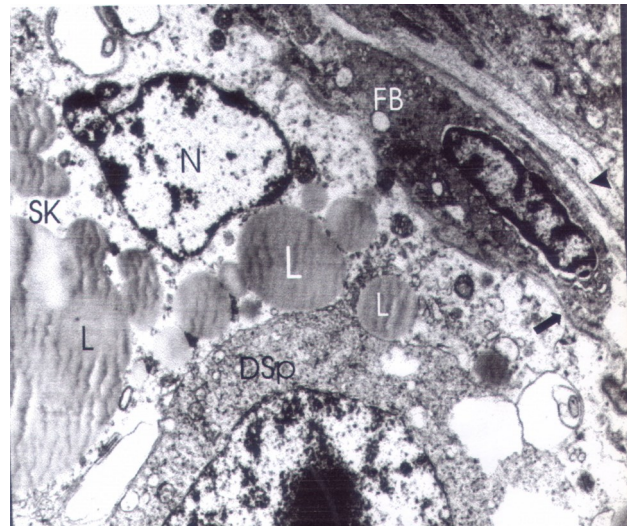


Fig. 2 A part of cytoplasm of Sertoli cell (SK) in degeneration in Ohrid trout. Presence of lipids (L) with different dimensions, prominent nucleus (N). Spermatogonium in degeneration (DSp). Visible interstitium with fibroblast (FB) in direct closeness of basal lamina (arrow), presence of collagenous fibrils (small arrow). Ultrathin section, 4.000x.

RESULTS

On a level of seminiferous lobules of Ohrid trout in dependence of annual cycle, cysts with different germinal generations can be present. In some spermatogonia, directly before the spawning, beginning degenerative changes can be noticed, i. e. on a level of some spermatogonia granular cytoplasm and granular chromatin, as well as a presence of lipids with low electron density can be noticed (Fig. 1). In the postspawning period, as the process goes on, i. e. final phase, except normal spermatogonia, there are some which show signs of degeneration and are characterized by unsymmetrical form and thick cytoplasm (Fig. 2, 3, 4). The nucleus of these cells doesn't have clear contours. It has an unsymmetrical form, condensed chromatin and karyopycnotic characteristics. On a level with certain seminiferous lobules spermatogonia which separate from the walls of the lobules can be observed. It has to be noted that spermatogonia which are situated next to Sertoli cells are degenerated, as well as the Sertoli cells are (Fig. 2, 3). Also, in the period of regeneration which follows the postspawning period, is characterized by the presence of spermatogonial generation for the following reproductive cycle. On a level with some seminiferous lobules spermatogonia in degeneration can be observed, which are manifested hyperchromatic characteristics of the nuclei or karyopycnosis has al-

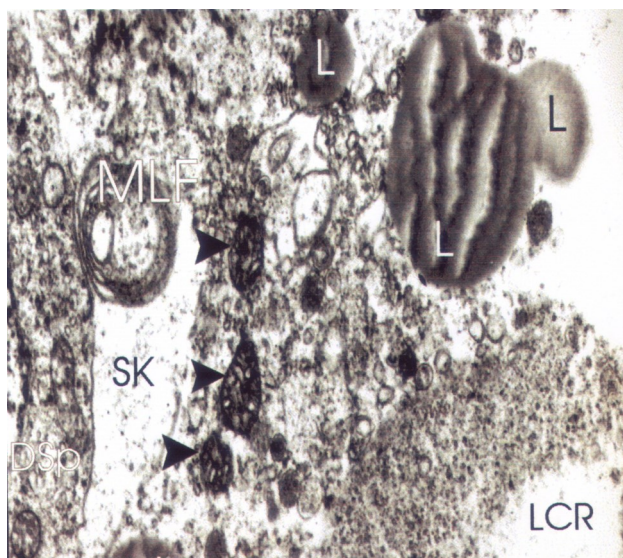


Fig. 3 A part of cytoplasm of Sertoli cell in degeneration, lysosomes with “myelin like” figures (MLF), lysed cytoplasmic regions (LCR), mitochondria in degeneration (small arrows), lipids (L) with different dimensions in Ohrid trout. A part of one spermatogonium in degeneration (DSp). Ultrathin section, 8.000x

ready happened with them. In Ohrid belvica the degeneration of spermatogonia are clearly noticed on ultrathin sections. The beginning degenerative changes of spermatogonia are manifested with cytoplasm with granular structure in which single vacuoles, disintegrated nuclear membrane and heterochromatic nucleus and nucleolus have been noticed (Fig. 5). Also, on ultrastructural level in the cytoplasm of degenerated spermatogonia, mitochondria with disintegrated crusts and lysed parts of the cytoplasm can be noticed (Fig. 6). Our results have pointed out that during the period of rebuilding of testicular parenchyma, i. e. the postspawning period, the degenerative changes which have been seen on a level of spermatogonial population, they can be explained as a normal following phenomenon which follows the initial phase of the future reproductive (spermatogenetic) cycle, whose intensive development happens in the later period, i. e. period of regeneration.

DISCUSSION

The studies of ultrastructural features of teleost spermatogenesis are scarce and they focused mostly on common carp (*Cyprinus carpio*), silver pomfret (*Pampus argenteus*), burbot (*Lota lota*), rock flounder (*Kareius bicoloratus*) and grey armored catfish (*Liposarcus anisitsi*) (Dadras et al. 2023) with other spe-

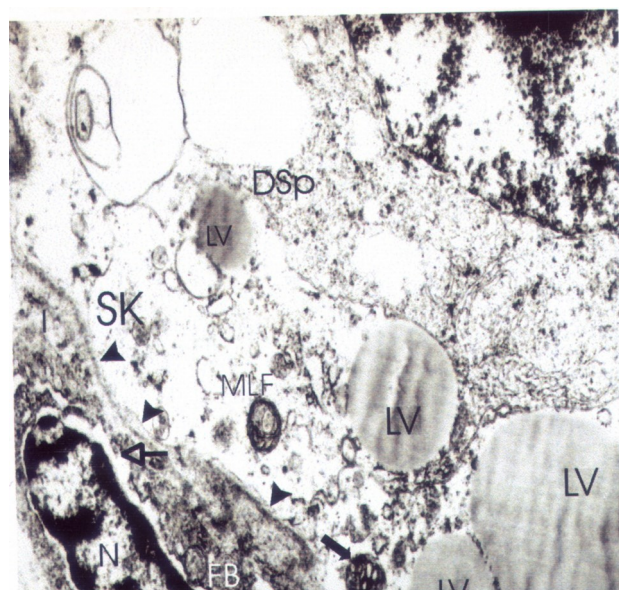


Fig. 4 A part of spermatogonium in degeneration (DSp) in direct closeness with Sertoli cell in degeneration in Ohrid trout. In the cytoplasm of Sertoli cell (SK) presence of lysosomes with “myelin like” figures (MLF), mitochondrion in degeneration (black arrow), lipid vacuoles (LV) with different dimensions. Visible basal lamina (small arrows). In the interstitium (I) fibroblast (FB) with prominent nucleus (n) with widened perinuclear space (arrow). Ultrathin section, 8.000x.

cies receiving less attention.

In the seminiferous lobules of Ohrid trout and Ohrid belvica except normal spermatogonia, we found out a presence of spermatogonia which show evident signs of degeneration, which are manifested by karyopycnosis, granular or vacuolated cytoplasm, completely homogenous mass with delaminated cell membrane, delamination of spermatogonia from the walls of the seminiferous lobules. In our preliminary research spermatogonial degeneration of the testes of Salmonidae, i. e. Ohrid trout and Ohrid belvica was noticed by Dimovska & Tavciovaska-Vasileva (1998), Tavciovaska-Vasileva (1999, 2001, 2002, 2004) and Tavciovaska-Vasileva & Rebok (2009). The degeneration of certain spermatogonia with *Perca fluviatilis* was noticed too by Kulaev (1927). Also, in the testes of Dojran perch presence of degenerated spermatogonia was stated (Tavciovaska-Vasileva, 1992, 1994). Similar formations, i. e. necrotic (lipophuscine) groups with *Fundulus heteroclitus* were noticed by Matthews (1938) and Lofts et al. (1966). Necrotic formations rich with lipids and PAS positive cells in the testes of *Salaria pavo* were noticed (Patzner & Seiwald, 1987). In the literature there are

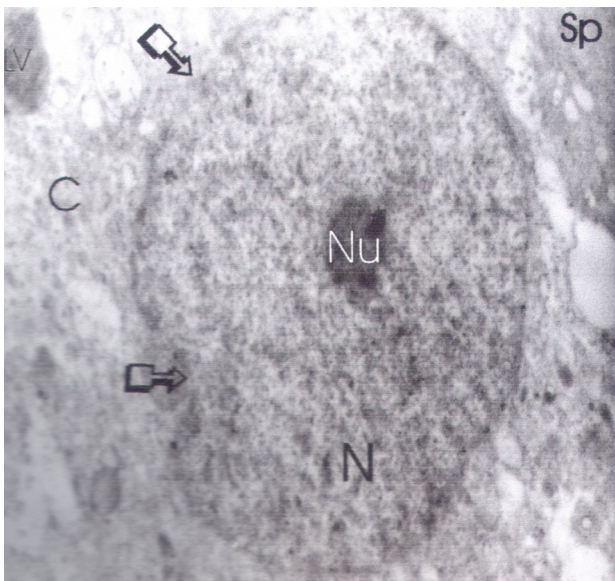


Fig. 5 Spermatogonium (Sp) in degeneration, cytoplasm with granular structure, single lipid vacuole (LV), disintegrated nuclear membrane (arrows), heterochromatic nucleus (N), homogenous nucleolus (Nu) in Ohrid belvica. Ultrathin section, 7.000x.

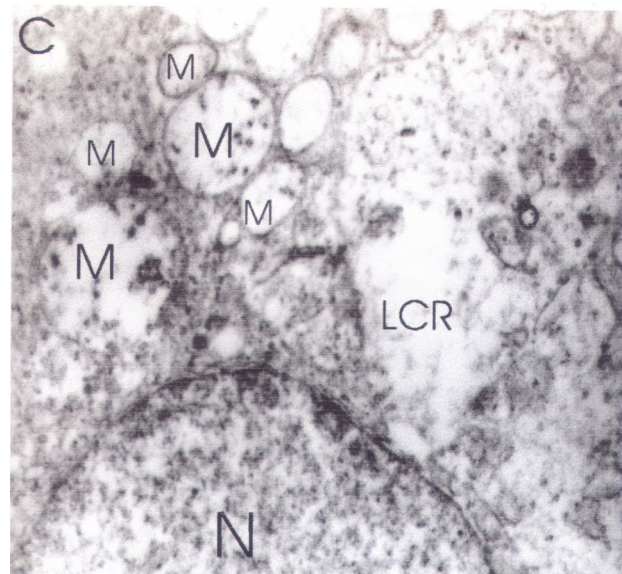


Fig. 6 A part of cytoplasm (C) and nucleus (N) of one spermatogonium in degeneration. In the cytoplasm presence of mitochondria (M) with disintegrated crusts and lysed parts of cytoplasm (LCR) in Ohrid belvica. Ultrathin section, 12.000x.

relatively a small number of data which point out the degenerative changes of spermatogonia with Teleostei during the annual reproductive cycle (Almeida et al., 2008; Leal et al., 2009; Print & Loveland, 2000). The degenerative processes which are visible on a level with the spermatogonial generation should be explained as a normal accompanying phenomenon which follows the initial phase of the future reproductive cycle, i. e. the proliferation and the differentiation of spermatogonia. This intensive development happens in the later period (period of regeneration), in contrast to a large number of data which concern other Vertebrata, especially for Mammalia (Roosen-Runge & Leik, 1968; Collins, 1987) which point to an enormous number of gonocytes which are exposed to degeneration during the fetal and early postnatal period.

CONCLUSION

On the basis of our research concerning the testes of Ohrid trout and Ohrid belvica in the postspawning period and spermatogonial population, we can conclude the following: in certain seminiferous lobules, besides spermatogonia with normal cytomorphological aspect, they can be noticed in degeneration, which is manifested with karyopycnosis, mitochondria with disintegrated crusts, vacuoles and poor cytoplasm, as well

as delamination from the walls of the lobules.

REFERENCES

- Almeida, F. F. L., Kristoffersen, C., Taranger, G. L., Schulz, R. W. (2008): Spermatogenesis in Atlantic Cod (*Gadus morhua*): A novel model of cystic germ cell development. *Biology of Reproduction*, 78 (1): 27-34.
- Collins, P. M., Pudney, J., Tsang, W. N. (1987): Postnatal differentiation of the gametogenic and endocrine functions of the testis of the tree-shrew (*Tupaia belangeri*). *Cell Tiss. Res.*, 25:681-687.
- Dadras, H., Dadras, F., Imentaj, A., Malinovskyi, O., Pěnka, T., Kolářová, J., & Policar, T. (2023). Fine ultrastructural features of germ cells and spermatozoa during spermatogenesis in the European grayling, *Thymallus thymallus* (Teleostei, Salmoniformes, Salmonidae). *Frontiers in Veterinary Science*, 10, 1188479.
- Dimovska, A., Tavchiovska-Vasileva, I. (1998): Citoloski alteracii na spermatogonijalnata populacija na Ohridskata belvica (*Salmothymus ochridanus* Steind.) vo postmrestitelniot period. 2 Kongres na biologite na Makedonija. Zbornik na apstrakti. Ohrid, Republika Makedonija.
- Kulaev, S. U. (1927): Nablodenija nad izmenenien semenikov recnogo okunja (*Perca fluviatilis* L.) v te-

- cenie godovogo cikla. Russk. Zool. Zurn., 7: 15-54.
- Leal, M. C., Cardoso, E. R., Nobrega, R. H., Batlouni, S. R., Bogerd, J., Franca, L. R., Schulz, W. (2009): Histological and stereological evaluation of Zebrafish (*Danio rerio*) spermatogenesis with an emphasis on spermatogonial generations. *Biology of Reproduction*, 81 (1): 177-187.
- Lofts, B., Pickford, G. E., Atz, J. W. (1966): Effects of Methyltestosterone on the testes of a hypophysectomized cyprinodont fish, *Fundulus heteroclitus*. *Gen. Comp. Endocrinol.*, 6: 74-88.
- Matthews, S. A. (1938): The seasonal cycle in the testes of *Fundulus*. *Biol. Bull.*, 75: 66-74.
- Patzner, R. A., Seiwald, M. (1987): Reproduction of *Bleinius pavo* (Teleostei, Blenniidae). VI. Testicular Cycle. *Zool. Anz.*, 219 (5/6): 265-273.
- Print, C. G., Loveland, K. L. (2000): Germ cell suicide: new insights into apoptosis during spermatogenesis. *BioEssays: news and reviews in molecular, cellular and developmental biology*, 22 (5): 423-430.
- Roosen-Runge, E. C., Leik, J. (1968): Gonocyte degeneration in the postnatal male ret. *Am. J. Anat.*, 122: 275-300.
- Tavciovaska-Vasileva, I. (1992): Histoloska struktura na semenikot na Dojranskata perkija (*Perca fluviatilis macedonica* Kar.) vo periodot po mrestenjeto. Magisterski trud. Skopje, Republika Makedonija.
- Tavciovaska-Vasileva, I. (1994): Spermatogonijalna degeneracija kako propraten fenomen na spermatogenezata vo postmrestitelniot period kaj Dojranskata perkija (*Perca fluviatilis macedonica* Kar.). *God. Zb. Biol.*, Skopje, 47: 189-198.
- Tavciovaska-Vasileva, I. (1999): Komparativni strukturni i ultrastrukturni karakteristiki na semenicite kaj Salmionidae (Pisces: Teleostei) od Ohridskoto Ezero vo postmrestitelniot period. Doktorska disertacija. Skopje, Republika Makedonija.
- Tavciovaska-Vasileva, I. (2001): Degeneration of spermatogonial population as a phenomenon which follows the proliferation and differentiation of spermatogonia of Ohrid trout (*Salmo letnica* Kar.) in the period after the spawning. *Veterinary Medicine*, VII (3-4): 89-92.
- Tavciovaska-Vasileva, I. (2002): Spermatogonial degeneration as a normal accompanying phenomenon of the reproductive cycle of Ohrid belvica (*Acantholingua ohridana*) during the postspawning period. XVII International Symposium on Morphological Sciences. Abstract book. Timisoara, Romania.
- Tavciovaska-Vasileva, I. (2004): Degeneration of spermatogonia-a normal phenomenon of the spermatogenesis of the Ohrid belvica (*Acantholingua ohridana*) during the period after the spawning. *Veterinary Medicine*, VIII(1-2): 58-61.
- Tavciovaska-Vasileva, I., Rebok, K. (2009): Ultrastructural features of degenerated spermatogonia of Ohrid trout (*Salmo letnica* Kar.) during the reproductive cycle. *Annual of Konstantin Preslavky University, Faculty of Natural Sciences, Shumen, Bulgaria*, Vol. XIX B6: 110-119.

